SEE GA DIFFERENTLY

GEOGRAPHIC ATROPHY (GA):

Imaging Guide for Early Detection and Monitoring

astellas

Taking a closer look at GA

A comprehensive eye examination with imaging can help with early detection, diagnosis, and monitoring of the progression of age-related macular degeneration (AMD) to GA.[1,2]

Detection and monitoring of AMD progression to GA can be achieved using imaging modalities such as optical coherence tomography (OCT), fundus autofluorescence (FAF), and color fundus photography (CFP).[1]

It is important to be vigilant and look for AMD in your patients so it can be detected as early as possible. This guide focuses on intermediate and late AMD, which are more likely to be the symptomatic stages of the disease.[3]

DIAGNOSTIC HALLMARKS

Early AMD

Multiple small (<63 µm) and few intermediate (63-124 µm) drusen, or retinal pigment epithelium (RPE) abnormalities.[4]

Intermediate AMD

Extensive intermediate drusen (63-124 µm) or more than 1 large drusen (≥125 µm). May also be accompanied by degenerative changes in the choriocapillaris, RPE, and photoreceptors.[2,4,5]

Advanced AMD (GA)

Progressive atrophy of choriocapillaris, RPE, and photoreceptors, as well as new and growing atrophic lesions.[2,6,7]

Optical coherence tomography (OCT)

Established as the standard base or reference modality in the early diagnosis of GA.[8,9]

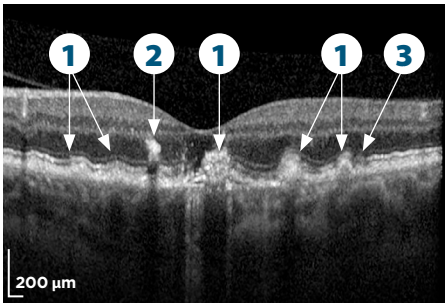

Image courtesy of Dr. Arshad Khanani

Intermediate AMD

1. Intermediate (63-124 µm) and large (≥125 µm) drusen[4]
2. Hyperreflective foci correspond to disruption of the RPE[10]
3. Detectable photoreceptor degradation[8]

The transition from intermediate AMD to GA is a critical time in progression.[11]

New OCT findings in patients with AMD may help determine the transition to GA and further aid in the development of a proper management plan, which may help to minimize the impact of GA.[11]

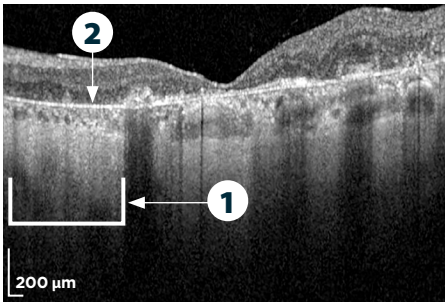

Image courtesy of Dr. Arshad Khanani

Advanced AMD (GA)

1. Choroidal hypertransmission[4]
2. RPE, photoreceptor, and choriocapillaris layer loss[9]

Fundus autofluorescence (FAF)

Used for diagnosis and monitoring progression by measuring the full area affected by GA.[12] FAF is a useful tool for visualizing progression when educating patients.

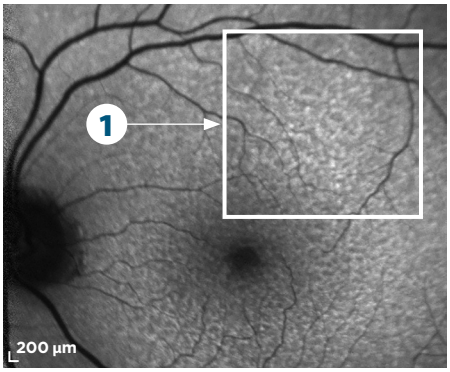

Image courtesy of Dr. Arshad Khanani

Intermediate AMD

1. Reticular pseudodrusen appearing as multiple, clustered, regularly networked, round areas of low-contrast hypoautofluorescence and may be prognostic of advancing GA[12,13]

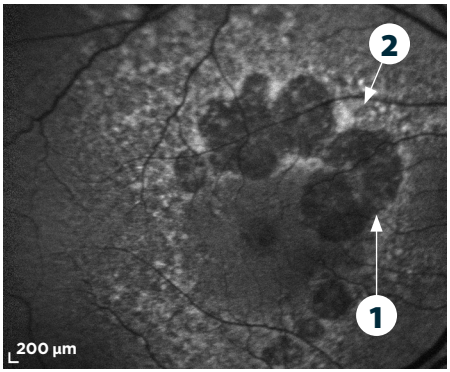

Image courtesy of Dr. David Lally

Advanced AMD (GA)

1. An area of hypoautofluorescence with a sharply demarcated border indicative of atrophic lesions[4]
2. Abnormal patterns of hyperautofluorescence surrounding atrophic lesions can indicate excessive lipofuscin accumulation that may reflect cellular dysfunction and is prognostic of GA progression[4]

Color fundus photography (CFP)

Can be used to establish a baseline and detect pigmentary changes as AMD progresses to GA.[1]

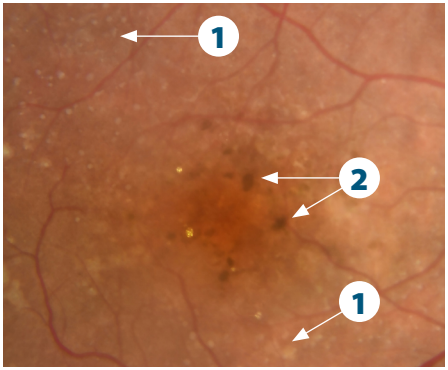

Image courtesy of Dr. Arshad Khanani

Intermediate AMD

1. Increase in number of intermediate (63-124 µm) drusen[4]
2. Areas of pigmentary change associated with RPE abnormalities[14]

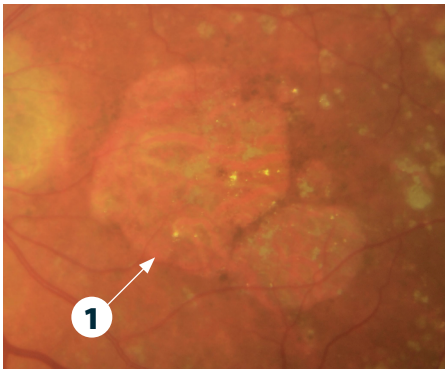

Image courtesy of Dr. Arshad Khanani

Advanced AMD (GA)

1. GA lesion border is sharply demarcated with increased choroidal vessel visibility[1]

TIP: A red-free filter on CFP can help to delineate retinal abnormalities.[15] This can be useful when sharing imaging with a patient.

iRORA vs cRORA

Incomplete RPE and outer retinal atrophy (iRORA), also known as nascent GA in the absence of choroidal neovascularization, represents an earlier phase of disease progression before advancing to complete RPE and outer retinal atrophy (cRORA).[8]

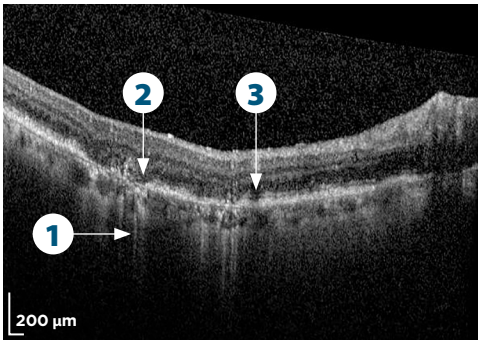

Image courtesy of Dr. Carl Danzig

iRORA[16]

1. Some hypertransmission present in the choroid, but it is discontinuous
2. A corresponding zone of attenuation and disruption of RPE with persistence of basal laminar deposits
3. Photoreceptor degeneration

cRORA is a more advanced stage of atrophy.[8]

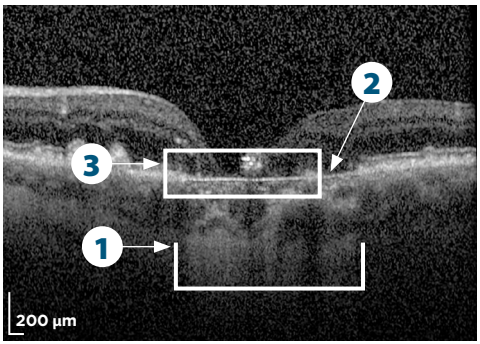

Image courtesy of Dr. Arshad Khanani

cRORA[8,*]

1. Area of choroidal hypertransmission ≥250 µm
2. Zone of attenuation/disruption of RPE ≥250 µm
3. Evidence of overlying photoreceptor degeneration, which includes ONL thinning, ELM loss, and EZ/IZ loss

*Absence of scrolled RPE or other signs of an RPE tear.

TIP: Proper optimization of instrumentation can minimize artifacts and improve the quality of imaging.[17] Work with your imaging partner to configure your instrument to your needs and specifications.

Lesion characteristics can predict rate of progression

Hyperautofluorescent FAF patterns can be predictive of the rate of GA progression. Rate of progression is slowest with no hyperautofluorescence or a focal pattern, and highest with banded and diffuse patterns. Eyes with diffuse-trickling patterns may also progress relatively quickly.[4]

Banded pattern

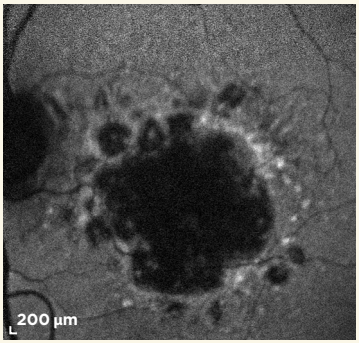

Image courtesy of Dr. Arshad Khanani

Diffuse pattern

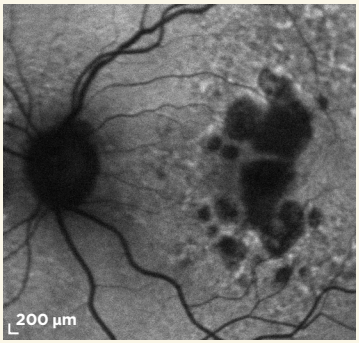

Image courtesy of Dr. Arshad Khanani

Diffuse-trickling pattern

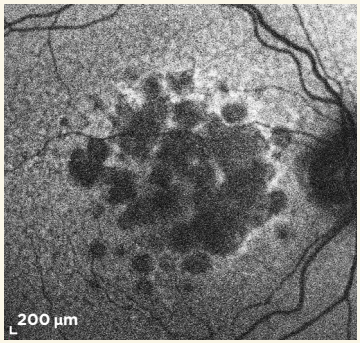

Image courtesy of Dr. Carl Danzig

Leveraging imaging in the early detection of GA is important to help minimize the impact of the disease.[11]

ELM=external limiting membrane; EZ=ellipsoid zone; IZ=interdigitation zone; ONL=outer nuclear layer.

References:

1. Holz FG, Sadda SR, Staurenghi G, et al. Imaging protocols in clinical studies in advanced age-related macular degeneration: recommendations from Classification of Atrophy Consensus Meetings *Ophthalmology*. 2017;124(4):464-478.
2. Flaxel CJ, Adelman RA, Bailey ST, et al. Age-related macular degeneration preferred practice pattern(R). *Ophthalmology*. 2020;127(1):P1-P65.
3. Stahl A. The Diagnosis and Treatment of Age-Related Macular Degeneration. *Dtsch Arztebl Int*. 2020;117 (29-30):513-520.
4. Fleckenstein M, Mitchell P, Freund KB, et al. The progression of geographic atrophy secondary to age-related macular degeneration. *Ophthalmology*. 2018;125(3):369-390.
5. Fleckenstein M, Keenan TDL, Guymer RH, et al. Age-related macular degeneration. *Nat Rev Dis Primers*. 2021;7(1):31.
6. Holz FG, Schmitz-Valckenberg S, Fleckenstein M. Recent developments in the treatment of age-related macular degeneration. *J Clin Invest*. 2014;124(4):1430-1438.
7. Boyer DS, Schmidt-Erfurth U, van Lookeren Campagne M, Henry EC, Brittain C. The pathophysiology of geographic atrophy secondary to age-related macular degeneration and the complement pathway as a therapeutic target. *Retina*. 2017;37(5):819-835.
8. Sadda SR, Guymer R, Holz FG, et al. Consensus definition for atrophy associated with age-related macular degeneration on OCT: classification of Atrophy Report 3 [published correction appears in *Ophthalmology*. 2019;126(1):177]. *Ophthalmology*. 2018;125(4):537-548.
9. Elsharkawy M, Elrazzaz M, Ghazal M, et al. Role of optical coherence tomography imaging in predicting progression of age-related macular disease: a survey. *Diagnostics (Basel)*. 2021;11(12):2313.
10. Fragiotta S, Abdolrahimzadeh S, Dolz-Marco R, Sakurada Y, Gal-Or O, Scuderi G. Significance of hyperreflective foci as an optical coherence tomography biomarker in retinal diseases: characterization and clinical implications. *J Ophthalmol*. 2021;2021:6096017.
11. Regillo CD, Nijm LM, Shechtman DL, et al. Considerations for the Identification and Management of Geographic Atrophy: Recommendations from an Expert Panel. *Clin Ophthalmol*. 2024;18:325-335.
12. Sadda SR, Chakravarthy U, Birch DG, et al. Clinical endpoints for the study of geographic atrophy secondary to age-related macular degeneration. *Retina*. 2016;36(10):1806-1822.
13. Xu L, Blonska AM, Pumariega NM, et al. Reticular macular disease is associated with multilobular geographic atrophy in age-related macular degeneration. *Retina*. 2013;33(9):1850-1862.
14. Heesterbeek TJ, Lores-Motta L, Hoyng CB, Lechanteur YTE, den Hollander AI. Risk factors for progression of age-related macular degeneration. *Ophthalmic Physiol Opt*. 2020;40(2):140-170.
15. Ly A, Nivison-Smith L, Assaad N, Kalloniatis M. Fundus autofluorescence in age-related macular degeneration. *Optom Vis Sci*. 2017;94(2):246-259.
16. Guymer RH, Rosenfeld PJ, Curcio CA, et al. Incomplete retinal pigment epithelial and outer retinal atrophy in age-related macular degeneration: classification of atrophy meeting report 4. Ophthalmology. 2020;127(3):394-409.
17. De Pretto LR, Moult EM, Alibhai AY, et al. Controlling for artifacts in widefield optical coherence tomography angiography measurements of non-perfusion area. *Sci Rep*. 2019;9(1):1-5.

SEE GA DIFFERENTLY

astellas

Copyright © 2026 Astellas Pharma Inc. or its affiliates.
All trademarks are the property of their respective owners.

MAT-SG-ACP-2026-00011 | May 2026